

Dysphagia Assessment and Treatment Planning

A TEAM APPROACH

Fourth Edition

Dysphagia Assessment and Treatment Planning

A TEAM APPROACH

Fourth Edition

Rebecca Leonard, PhD
Katherine A. Kendall, MD





5521 Ruffin Road
San Diego, CA 92123

e-mail: info@pluralpublishing.com
website: <http://www.pluralpublishing.com>

Copyright 2019 © by Plural Publishing, Inc.

Typeset in 10.5/13 Palatino by Flanagan's Publishing Services, Inc.
Printed in Korea by Four Colour Print Group

All rights, including that of translation, reserved. No part of this publication may be reproduced, stored in a retrieval system, or transmitted in any form or by any means, electronic, mechanical, recording, or otherwise, including photocopying, recording, taping, Web distribution, or information storage and retrieval systems without the prior written consent of the publisher.

For permission to use material from this text, contact us by
Telephone: (866) 758-7251
Fax: (888) 758-7255
e-mail: permissions@pluralpublishing.com

Every attempt has been made to contact the copyright holders for material originally printed in another source. If any have been inadvertently overlooked, the publishers will gladly make the necessary arrangements at the first opportunity.

Library of Congress Cataloging-in-Publication Data

Names: Leonard, Rebecca, editor. | Kendall, Katherine (Staff physician), editor.

Title: Dysphagia assessment and treatment planning : a team approach / [edited by] Rebecca Leonard, Katherine A. Kendall.

Description: Fourth edition. | San Diego : Plural Publishing, [2019] | Includes bibliographical references and index.

Identifiers: LCCN 2017046023 | ISBN 9781635500097 (alk. paper) | ISBN 1635500095 (alk. paper)

Subjects: | MESH: Deglutition Disorders—diagnosis | Deglutition Disorders—therapy | Patient Care Planning | Patient Care Team

Classification: LCC RC815.2 | NLM WI 258 | DDC 616.3/23—dc23
LC record available at <https://lcn.loc.gov/2017046023>

Contents

Introduction	vii
Multimedia List	xi
Acknowledgments	xii
Contributors	xiii
1 Anatomy and Physiology of Deglutition <i>Katherine A. Kendall</i>	1
2 Head and Neck Physical Exam <i>Katherine A. Kendall</i>	27
3 Clinical Swallow Evaluation <i>Susan J. Goodrich and Alice I. Walker</i>	37
4 Endoscopy in Assessing and Treating Dysphagia <i>Rebecca Leonard</i>	53
5 Radiographic Evaluation of the Pharynx and Esophagus <i>Jacqui Allen</i>	73
6 Dynamic Fluoroscopic Swallow Study: Swallow Evaluation with Videofluoroscopy <i>Susan McKenzie and Rebecca Leonard</i>	85
7 DSS: A Systematic Approach to Analysis and Interpretation <i>Susan McKenzie and Rebecca Leonard</i>	105
8 Dynamic Swallow Study: Objective Measures and Normative Data in Adults <i>Rebecca Leonard</i>	125
9 Other Technologies in Dysphagia Assessment <i>Maggie A. Kuhn</i>	157
10 The Treatment Plan <i>Rebecca Leonard and Katherine A. Kendall</i>	169

11	Nursing Evaluation and Care of the Dysphagic Patient <i>Ann E. F. Sievers</i>	221
12	Nutritional Concerns and Assessment in Dysphagia <i>Beverly Lorens and Katherine A. Kendall</i>	243
13	Pediatric Clinical Feeding Assessment <i>Anna Miles</i>	279
14	Esophageal Phase Dysphagia <i>Peter C. Belafsky and Catherine J. Rees Lintzenich</i>	299
15	Neurogenic Dysphagia <i>Jacqui Allen</i>	309
16	Dysphagia in Head and Neck Cancer Patients <i>Katherine A. Kendall</i>	327
17	Laryngopharyngeal Reflux <i>Catherine J. Rees Lintzenich and Peter C. Belafsky</i>	355
18	Spinal Abnormalities in Dysphagia <i>Derrick R. Randall</i>	369
	Index	379

Introduction

Dysphagia Assessment and Treatment Planning: A Team Approach is now in its fourth edition, which speaks to our continuing emphasis on a multidisciplinary approach to dysphagia, but also, to the willingness of original, new and extended “team” members to be involved in this project. We very much appreciate everyone’s contributions!

The organization of the book has changed, with chapters concerned with assessment techniques coming first, and material addressing special populations comprising the latter portion of the text. This reflects what is likely a more typical approach to dysphagia in graduate courses concerned with the topic, and one that we hope complements teaching of the subject matter. Also new are PowerPoint slides accompanying each chapter hosted on a PluralPlus companion website. The slides are intended to highlight each chapter’s major points, with supplemental content then added as desired by individual instructors. We are also including materials on the website that can be used to complement chapter content. These have been developed by Dr. Barkmeier-Kraemer, first author of the text’s accompanying workbook, for a graduate dysphagia course that utilized the text. Our plan is to continue to update and add to these materials over the course of the next few years, thereby allowing the book to be a more dynamic, evolving source

of educational material, as opposed to a static resource.

Some information in the new edition represents updates on material previously presented. In a few cases—for example, head and neck anatomy (Chapter 1) and the clinical head and neck examination (Chapter 2)—information previously presented has not changed, though some edits to the existing text have been made. Similarly, our approach to endoscopy (Chapter 4) remains the same, though new possibilities for quantifying what have previously been only subjective observations are mentioned. Improvements in endoscopic equipment have also continued, contributing primarily to improved diagnostic capabilities, but also enhancing the differentiation of observations critical to oral-pharyngeal dysphagia. Clinical evaluation of swallowing (Chapter 3), incorporating both bedside and actual clinical evaluations, is quite comprehensive and has undergone minimal updating, as well. In other cases, substantial changes are obvious in the material.

For example, the pediatrics chapter (Ch. 13) has been written by Anna Miles, Ph.D., a speech-language pathologist from New Zealand who works in both medical and academic settings. Dr. Miles has expanded this chapter to address specific problems and needs not only of infants, which was a primary

focus of earlier chapters, but rather, the entire spectrum of childhood. This is an excellent addition to the book, one that provides both practical and data-based evidence for assessing and treating dysphagia in infants and children.

A brand-new addition to the book is Chapter 18 by Dr. Derrick Randall, who completed a laryngology fellowship at UC Davis and is now practicing at the University of Calgary, Alberta, Canada. Dr. Randall's chapter addresses dysphagia associated with alterations to the spine as a consequence of either disease or surgery. His information not only is current, but also provides practical information to students and clinicians who are, or will be, seeing these patients in clinical practice. In our own setting at UC Davis, this population is substantial, and we believe this is likely to be true of many settings, in particular those in which outpatients are evaluated and treated. We felt we should address this population in the current edition, and Dr. Randall's chapter nicely fulfills this need.

Chapters dealing with nursing (Chapter 11) and nutrition (Chapter 12) retain much of the information previously presented but have been updated to incorporate the latest recommendations in nursing care and dietary considerations for patients experiencing dysphagia. Similarly, chapters addressing special populations, including neurogenic disease (Chapter 15) and head and neck cancer (Chapter 16), provide details regarding the unique features of these pathologies, as well as incorporating the latest information regarding dysphagia and approaches to treatment pertinent to each group.

Gastroesophageal reflux continues to be a major issue in many dysphagic

patients, and is once again the subject of an entire chapter (Chapter 17). A chapter devoted to the esophagus (Chapter 14) addresses both esophageal diseases and their treatments, and diagnostic tools used to evaluate them. Other tools used to evaluate dysphagia, with descriptions of their use and updates on their emergence, are addressed in Chapter 9, "Other Technologies in Dysphagia Assessment." This chapter, authored by Dr. Maggie Kuhn, laryngologist from UC Davis, provides an excellent overview of tools, including ultrasound and functional MRI, for which continued exploration has demonstrated unique potential in the assessment of dysphagia. Material presented will be informative for those just being introduced to dysphagia, as well as to those with substantial experience in the field. SLP deglutologists who are expanding their practices to include instrumental techniques such as manometry and perhaps other esophageal assessments, will find this information of particular interest. "GOOSE" (guided observation of swallowing in the esophagus), for example, is described in the chapter as the esophageal equivalent of FEES for the upper aerodigestive tract.

As with previous editions, information dedicated to fluoroscopic evaluation, or the dynamic swallow study (DSS), is emphasized (Chapters 6–8, 15). In part, this is due to the fact that fluoroscopy continues to be a major diagnostic tool in patients with dysphagia. Advances in MRI (magnetic resonance imaging) have emerged in the last few years—for example, it now has the potential to capture data in "real-time." This, in addition to its excellent soft tissue definition and non-invasiveness, makes it a very desirable candidate

for replacing fluoro (discussed in Dr. Allen's updated chapter, "Radiographic Evaluation of the Pharynx and Esophagus," as well as in Chapter 9). However, a number of major problems must still be resolved before this is likely to happen, some of them technical, and others related to cost and availability. When (or if) it does happen, the ability to quantify mechanical characteristics, a major strength of fluoroscopy, will be retained and, hopefully, expanded. It is, in fact, this feature of fluoroscopy that our Team found to be so valuable in learning about swallowing, and is another major reason we have emphasized fluoroscopy in every edition of this text. In short, attempting to measure mechanical features of swallowing is simply an excellent way to learn about it.

A major new inclusion in the current edition are materials utilizing a new software program, "Swallowtail," which permits the all-in-one measurement, display and storage of timing, displacement and other measures from fluoroscopic studies. Though the program does not exclude clinician judgment regarding what to measure, or where, once this information has been determined, the software does permit expedient, and in some cases, semi-automatic measurement. Examples of measurements possible with the program, and opportunities to actually try out the software online, are available with both the text and the workbook. Our hope is that these resources will be used, for example, as an outside assignment for graduate students, as a test site for clinicians interested in experimenting with objective measurements, or simply as a means of being introduced to measurement possibilities associated with fluoroscopic swallow studies.

The treatment chapter (Chapter 10) has been updated to reflect the current status of therapeutic approaches previously considered in treating dysphagic patients. Since the last edition of this book, research has in some cases demonstrated the need for critical scrutiny and rethinking of strategies once widely applied. In others, careful research has led to new and promising approaches to intervention that will be further elaborated as they are put to the test and stringently evaluated. Our hope with this chapter is that we have provided sufficient detail for readers to understand the concepts behind a particular treatment, or category of treatment, and that they will then go beyond the text to acquire a deeper understanding, or mastery, of strategies of interest.

A workbook, authored by Dr. Julie Barkmeier-Kraemer, once again accompanies this new edition of the text. We are hopeful that readers will consider the two publications as a "paired set," in particular, since information and exercises outlined in the workbook are based on content of chapters in the book. Our feeling is that the combination of both works provides an excellent and effective means of learning about dysphagia, for students just being introduced to the area and, to practicing professionals who wish to broaden their understanding of current practices within this complex field.

As noted previously, the participation of physicians, nurse specialists, dietitians and SLP deglutologists in the preparation of this book speaks to the recognition of the value of a team approach to dysphagia. We believe, firmly, that the best approach to this serious and often debilitating condition is one that exploits the knowledge-base,

skills, and experience of individual specialists who bring their own unique talents to the assessment and treatment of dysphagic patients. In our own experience, this endeavor has proved a continual source of education, challenge

and satisfaction. We hope this edition of the text, and the accompanying workbook, will inspire others with similar interests to identify and maximize the possibilities for teamwork in their own settings.

Multimedia List

Chapter 1

Video 1–1. Straw Drinking

Chapter 4

Video 4–1. VPPORT

Video 4–2. OROPHX

Video 4–3. HYPOPHX

Video 4–4. FEESPT1

Video 4–5. FEESPT2

Chapter 6

Video 6–1. ZDtwoviews

Video 6–2. A/P Aspiration

Chapter 7

Video 7–1. NrmPhPeristalsis

Video 7–2. AbsIncPhPeristalsis

Video 7–3. ExcPhPeristalsis

Video 7–4. AbsIncEpigInv

Video 7–5. ASPBefore

Video 7–6. ASPDuring

Video 7–7. ASPAfter

Video 7–8. DiffEsophSpasm

Video 7–9. Stasis

Chapter 8

Video 8–1. BOLTRANSITWALL
GESTTIMING

Video 8–2. BolusTransitTime

Video 8–3. YngEldSwallow

Video 8–4. BP1AEcl

Video 8–5. Hmax

Video 8–6. PCR

Video 8–7. PESmax

Video 8–8. HL

Video 8–9. Calibration

Video 8–10. Hold

Video 8–11. BCR

Chapter 9

Video 9–1. Goose

Chapter 10

Video 10–1. Strategy 1

Video 10–2. Strategy 2A

Video 10–3. Strategy 2B

Video 10–4. Strategy 3

Video 10–5. Strategy 4

Video 10–6. Strategy 5

Video 10–7. Strategy 6

Video 10–8. Swallowing Expansion
Device [SED]: Fluoroscopy

Video 10–9. Swallowing Expansion
Device [SED]: Endoscopy

Video 10–10. Double Balloon
Dilation

Chapter 18

Video 18–1. CSpineBolusConsist
Manipulation

Video 18–2. CSpineBolusVol
Manipulation

Video 18–3. CSpineBolusRedirect

Acknowledgments

The authors extend a sincere “thank you” to the members of the UC Davis Dysphagia Team, past and present, as well as to our colleagues at other institutions, for their generosity and expertise in the preparation of this text. Our “team” experience at UCD has convinced us that a highly interactive, interdisciplinary group of individuals with unique backgrounds and skill sets represents an ideal approach to dysphagia management, as well as a perpetual source of continuing edu-

cation for individual members. We are hopeful that the text will inspire other professionals to develop similar resources in their own settings. We also thank those patients and volunteer subjects who have played a role in materials used in the book, as well as in our collection of normative and other data. These individuals have graciously shared their time and experiences with us, and we gratefully acknowledge their contributions.

Contributors

Jacqui Allen, MD, FRACS

Otolaryngologist, Senior Lecturer
University of Auckland
North Shore Hospital
Takapuna, Auckland
New Zealand
Chapters 5, 15

Peter C. Belafsky, MD, MPH, PhD

Professor & Director, Center for Voice
& Swallowing
Department of Otolaryngology
University of California, Davis
Sacramento, California
Chapters 14, 17

Susan J. Goodrich, MS

Senior Speech Pathologist
Voice Speech Swallow Center
Department of Otolaryngology
University of California, Davis
Sacramento, California
Chapters 3, 13

Katherine A. Kendall, MD, FACS

Professor
Division of Otolaryngology
University of Utah
Salt Lake City, Utah
Chapters 1, 2, 10, 16

Maggie A. Kuhn, MD

Assistant Professor
Department of Otolaryngology–Head
and Neck Surgery

University of California, Davis
Davis, California
Chapter 9

Rebecca Leonard, PhD

Professor, Emeritus, Department of
Otolaryngology–Head and Neck
Surgery
University of California, Davis
Sacramento, California
Chapters 4, 6, 7, 8, 10

Anna Miles, PhD

Senior Lecturer
Speech Science
The University of Auckland
Auckland, New Zealand
Chapter 13

Beverly Lorens, MS, RD

Senior Clinical Dietitian, retired
Food and Nutrition Services
University of California Davis Medical
Center
Sacramento, California
Academy of Nutrition and Dietetics
Chapter 12

Susan McKenzie, MS

Senior Speech Pathologist
Voice and Swallowing Center
University of California Davis
Sacramento, California
Chapters 6, 7

Derrick R. Randall, MD, MSc, FRCSC

Section of Otolaryngology–Head and
Neck Surgery
Department of Surgery
University of Calgary
Calgary, Canada
Chapter 18

Catherine J. Rees Lintzenich, MD

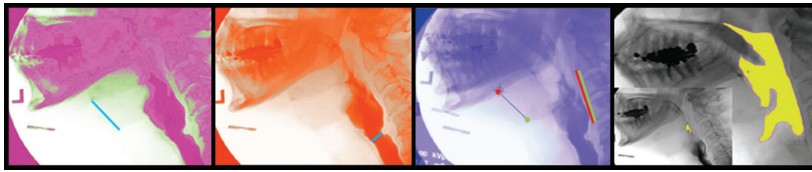
Associate Professor Otolaryngology
Head and Neck Surgery
Center for Voice and Swallowing
Disorders
Wake Forest University School of
Medicine
Winston-Salem, North Carolina
Chapters 14, 17

**Ann E. F. Sievers, RN, MA,
CORLN**

ENT Nurse Expert
Department of Patient Care Services
and Otolaryngology
University of California, Davis
Sacramento, California
Chapter 11

Alice I. Walker, MS

Senior Speech Language Pathologist
Department of Otolaryngology
University of California, Davis
Sacramento, California
Chapter 3



1

Anatomy and Physiology of Deglutition

Katherine A. Kendall

Familiarity with the anatomy and physiology of normal deglutition enables a more focused approach to the evaluation of patients with disordered swallowing. This chapter discusses those head and neck structures involved in swallowing and reviews the sequence of events resulting in a successful swallow.

The oral cavity, oropharynx, and esophagus can be thought of as a series of expanding and contracting chambers, divided by muscular sphincters. Propulsion of a bolus through this part of the alimentary tract is the result of forces or positive pressure developed behind the bolus, as well as a vacuum or negative pressure developed in front of the bolus. The creation of propulsion pressures depends on the sequential contraction and expansion of the chambers of the upper aerodigestive tract and the competency of the sphincters divid-

ing the chambers. Any disturbance in the functional elements or coordination of this system is likely to result in less efficient transfer of a bolus from the oral cavity to the stomach, resulting in dysphagia. Swallowing involves coordination of the sequence of activation and inhibition for more than 25 pairs of muscles in the mouth, pharynx, larynx, and esophagus. An understanding of how the structures of the head and neck interact and coordinate to bring about the propulsion pressures required for normal swallowing is vital for the clinician involved in the evaluation and treatment of patients with swallowing complaints.

For simplicity, the act of deglutition is traditionally divided into four parts: the preparatory phase, the oral phase, the pharyngeal phase, and the esophageal phase (Dodds, Stewart, & Logemann, 1990; Miller, 1982).

PREPARATORY PHASE

The preparatory phase of swallowing includes mastication of the bolus, mixing it with saliva, and dividing the food for transport through the pharynx and esophagus. The preparatory phase takes place in the oral cavity, the first chamber in the swallowing system. This oral preparatory phase of swallowing is almost entirely voluntary and can be interrupted at any time.

During bolus preparation, facial muscles play a role in maintaining the bolus on the tongue and between the teeth for chewing. Specifically, the orbicularis oris muscle, the circular muscle of the lips, maintains oral competence and can be considered as the first

sphincter of the swallowing system. The buccinator muscle of the cheek contracts to keep the bolus from pooling in the pockets formed by the gingival buccal sulci. These muscles receive neural input from the facial nerve or cranial nerve VII (Figures 1-1A, 1-1B, and 1-1C).

Most of the movement and positioning of the bolus is carried out by the tongue muscles. In addition to four intrinsic muscles, the tongue has four extrinsic muscles: the genioglossus, palatoglossus, styloglossus, and hyoglossus muscles (Figure 1-2). Along with the genioglossus muscle, the intrinsic muscles act primarily to alter the shape and tone of the tongue while the other three extrinsic muscles aid in

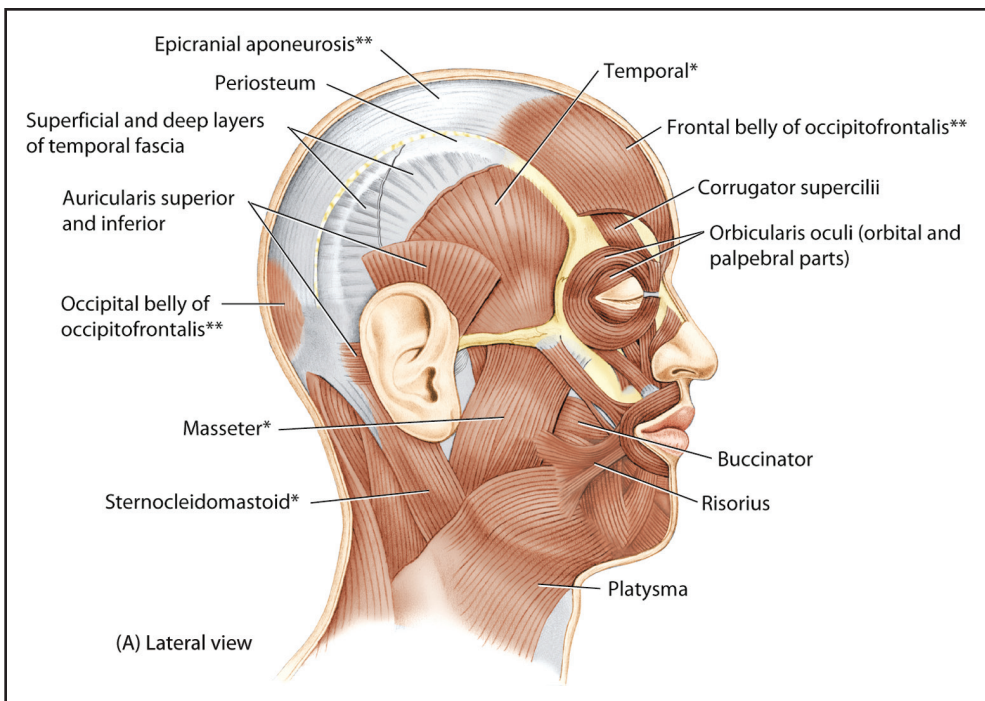


Figure 1-1. A. Facial musculature shown in relationship to muscles of head and neck. (Reprinted with permission from Moore & Dalley, 2006, *Clinically Oriented Anatomy*, 5th ed., Williams and Wilkins, Baltimore, p. 934, Figure 7-4a.) *continues*

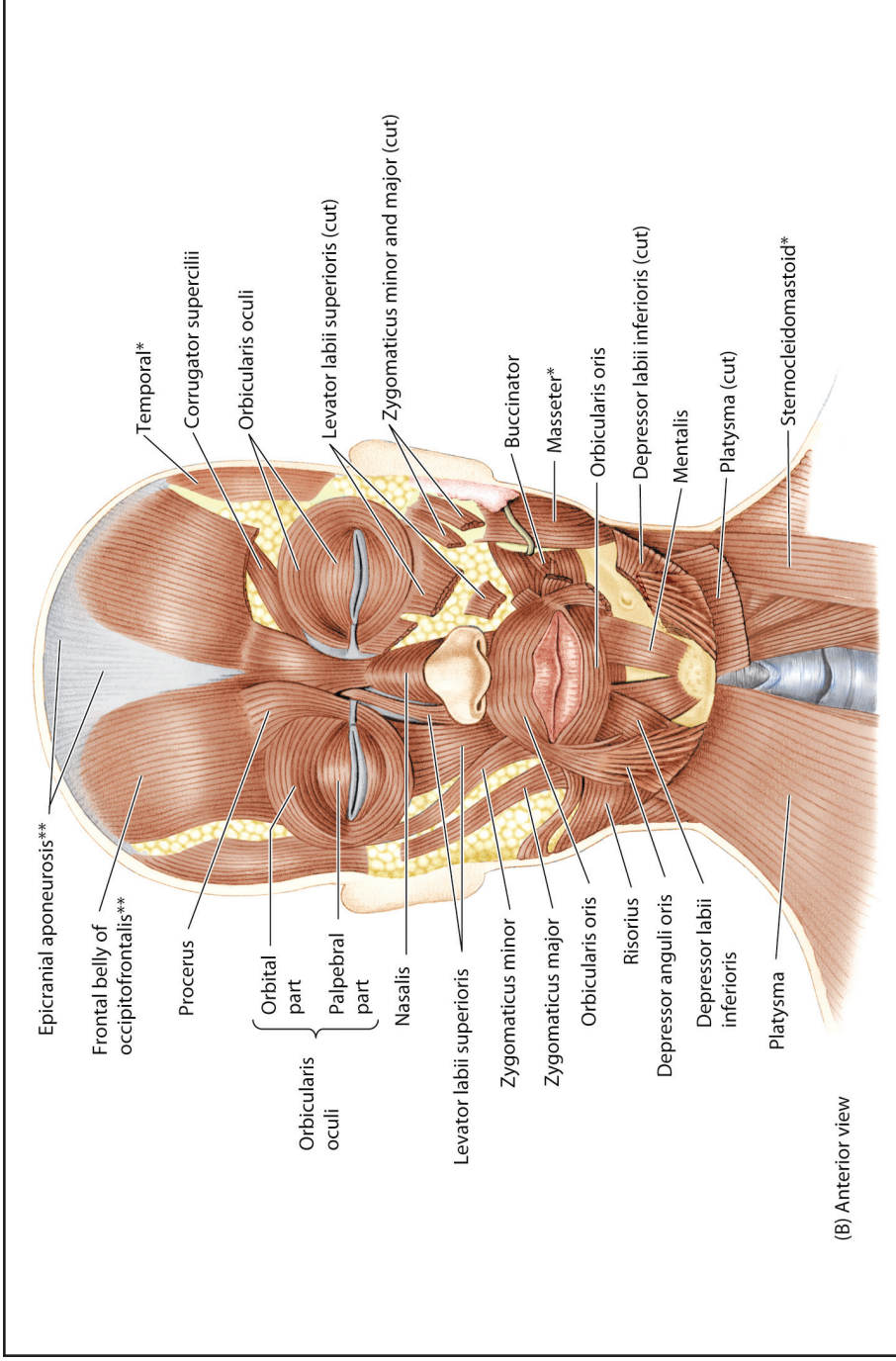


Figure 1-1. continued **B.** Facial musculature and buccinator muscle, anterior view. (Reprinted with permission from Moore & Dalley, 2006, *Clinically Oriented Anatomy*, 5th ed., Williams and Wilkins, Baltimore, p. 935, Figure 7-4b.) continues

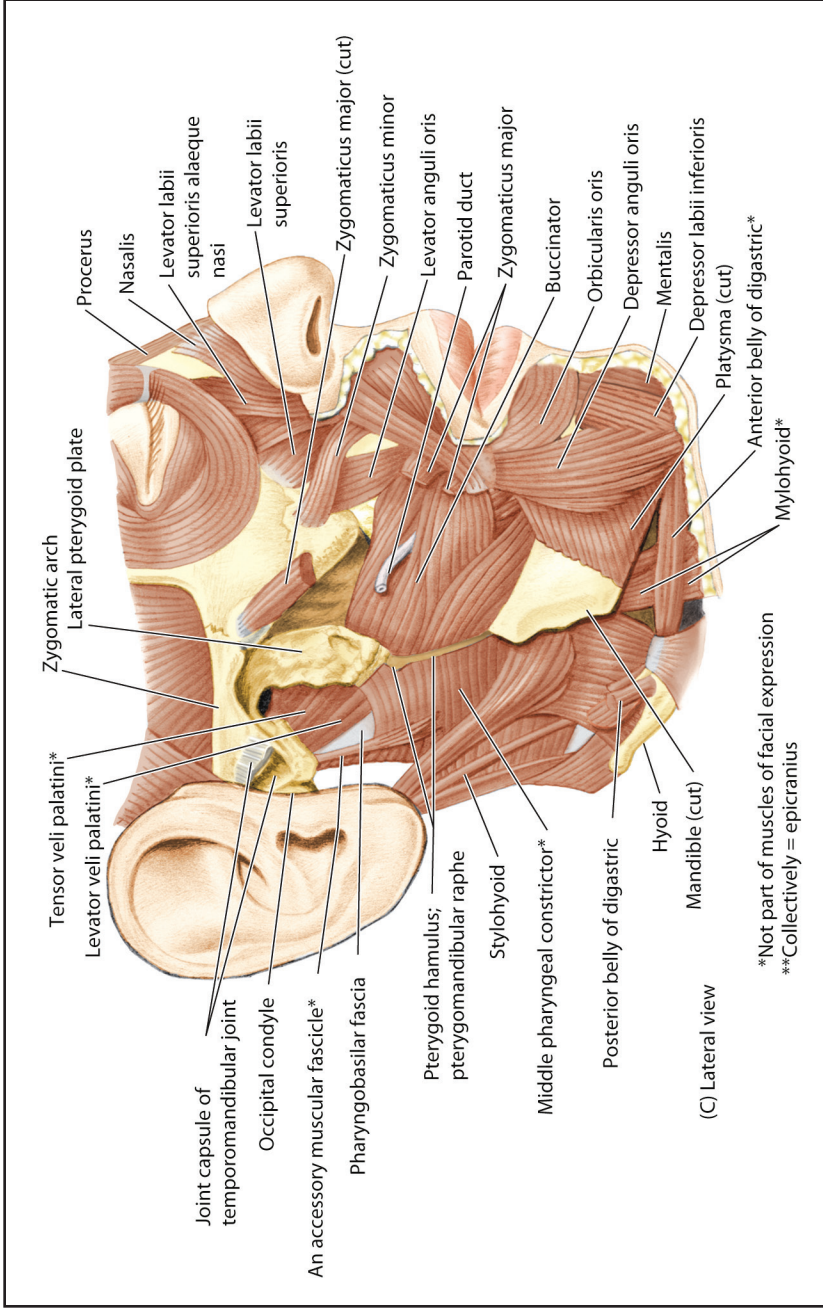


Figure 1-1. continued **C.** Facial musculature, lateral view. (Reprinted with permission from Moore & Dalley, 2006, *Clinically Oriented Anatomy*, 5th ed., Williams and Wilkins, Baltimore, p. 935, Figure 7-4c.)

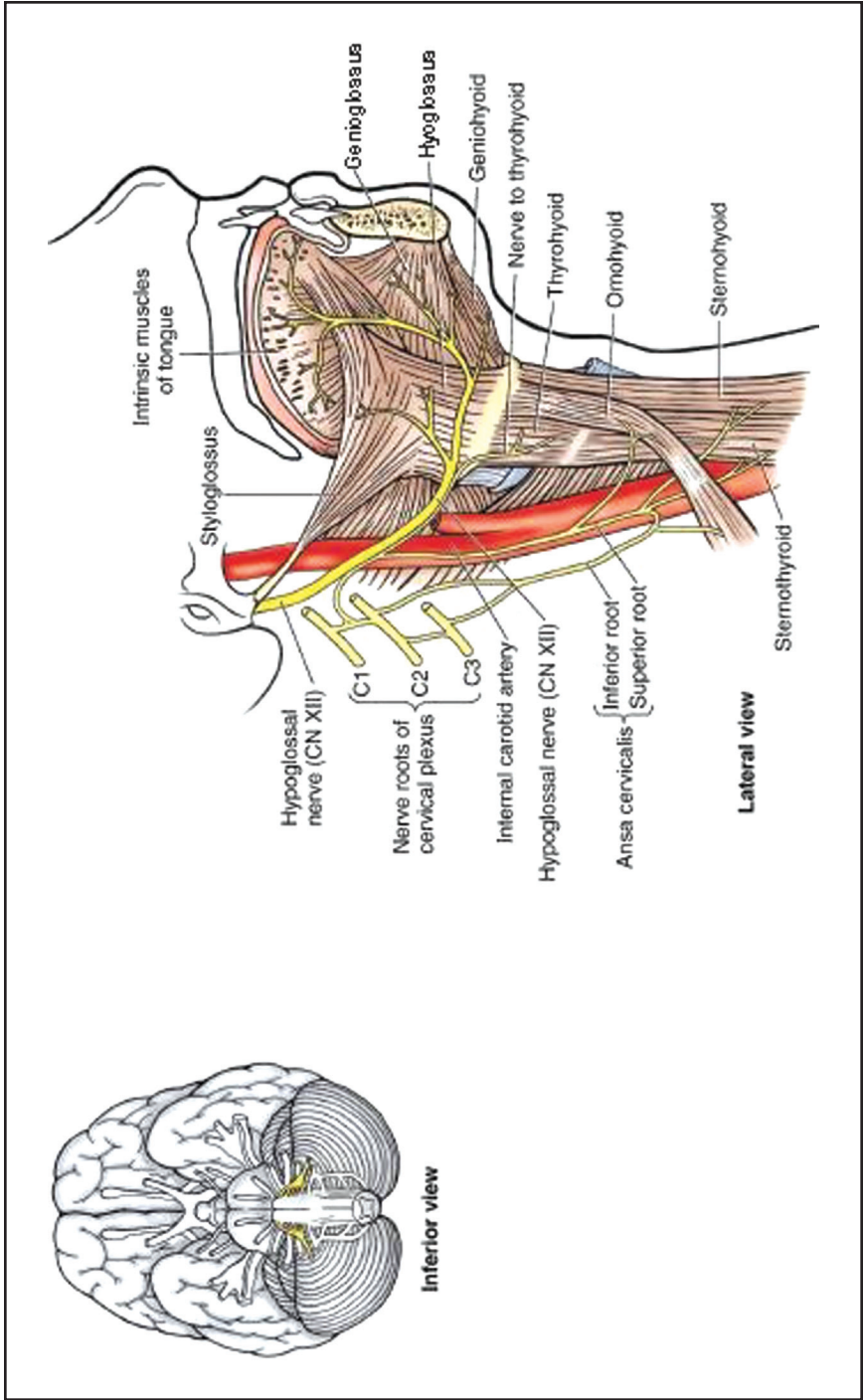


Figure 1-2. Distribution of the hypoglossal nerve. (Reprinted with permission from Moore & Dalley, 2006, *Clinically Oriented Anatomy*, 5th ed., Williams and Wilkins, Baltimore, p. 1154, Figure 9-15.)

the positioning of the tongue relative to other oral cavity and pharyngeal structures. Cranial nerve XII, the hypoglossal nerve, carries the motor nerve fibers that innervate both the intrinsic and extrinsic tongue muscles, except for the palatoglossus muscle (see Figure 1–2). A branch of the pharyngeal plexus from the vagus nerve (X) sends motor fibers to innervate the palatoglossus muscle. A high density of mechanoreceptors within and on the surface of the tongue indicates that the tongue is an important sensory region for determining the size of the bolus. Sensory information from the anterior two-thirds of the tongue is carried back to central swallowing control centers via the lingual nerve, a branch of the trigeminal nerve or cranial nerve V. Sensory information from the posterior one-third of the tongue is carried centrally by the glossopharyngeal nerve, or cranial nerve IX (Figures 1–3A and 1–3B). During the bolus preparatory phase of deglutition, the posterior part of the tongue elevates against the soft palate, which pushes downward to keep the bolus from escaping prematurely into the pharynx. The palate is the second sphincter in the swallowing system. Contraction of the palatoglossus muscles approximates the palate and posterior tongue, effectively closing the back of the oral cavity (Figures 1–4 and 1–5).

Mastication of the bolus involves the masseter muscles, the temporalis muscles, and the medial and lateral pterygoid muscles. This muscle group is known collectively as the muscles of mastication. Motor fibers controlling the contraction of these muscles are carried in branches of the trigeminal nerve (V) (Figure 1–6).

Salivation

Successful transfer of a food bolus from the oral cavity into the esophagus requires the mixing of the bolus with saliva. Saliva lubricates and dilutes the bolus to a consistency proper for swallowing. Saliva contains two major types of protein secretion: an enzyme for digesting starches, and mucous for lubricating purposes. Normal salivary secretion ranges from 1.0 to 1.5 liters per day. Saliva also plays an important role in maintaining healthy oral tissues. It is bacteriostatic and controls the pathogenic bacteria normally present in the oral cavity that are largely responsible for dental caries. The secretion of saliva is controlled by the salivatory nucleus in the brainstem. The nerve fibers of the parasympathetic nervous system carry signals from the salivatory nucleus to the salivary glands (Guyton, 1981).

ORAL PHASE

The bolus is propelled from the oral cavity to the pharynx during the oral phase of swallowing. The top of the tongue is placed on the superior alveolar ridge behind the maxillary central incisors. Voluntary opening of the pharynx then begins with elevation of the soft palate and depression of the posterior tongue (see Video 1–1 of straw drinking on the companion website). In this way, there is expansion of the posterior oral cavity and a chute forms down which the bolus moves into the pharynx. Elevation of the palate occurs as a result of contraction of the levator veli palatini muscle. The levator veli palatini muscle receives motor innervation from the



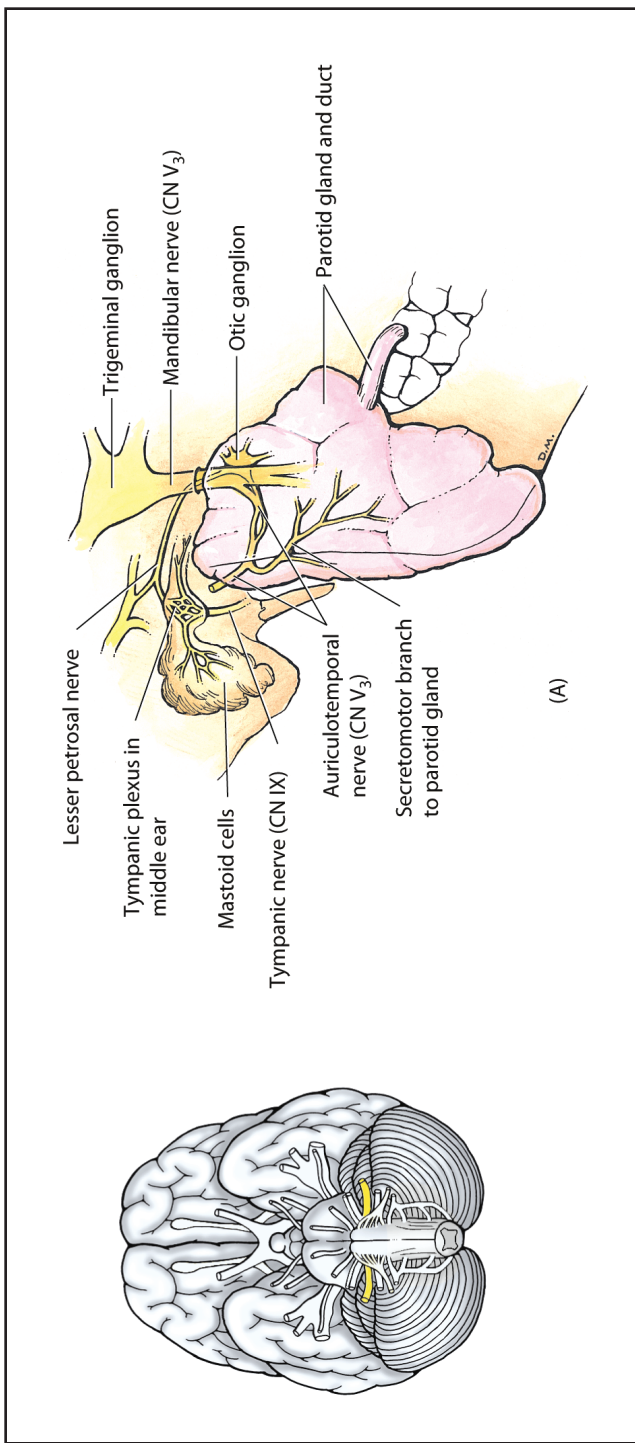


Figure 1-3. Distribution of the glossopharyngeal nerve (A, B). (Reprinted with permission from Moore & Dalley, 2006, *Clinically Oriented Anatomy*, 5th ed., Williams and Wilkins, Baltimore, p. 1148, Figure 9-10B.) (continues)

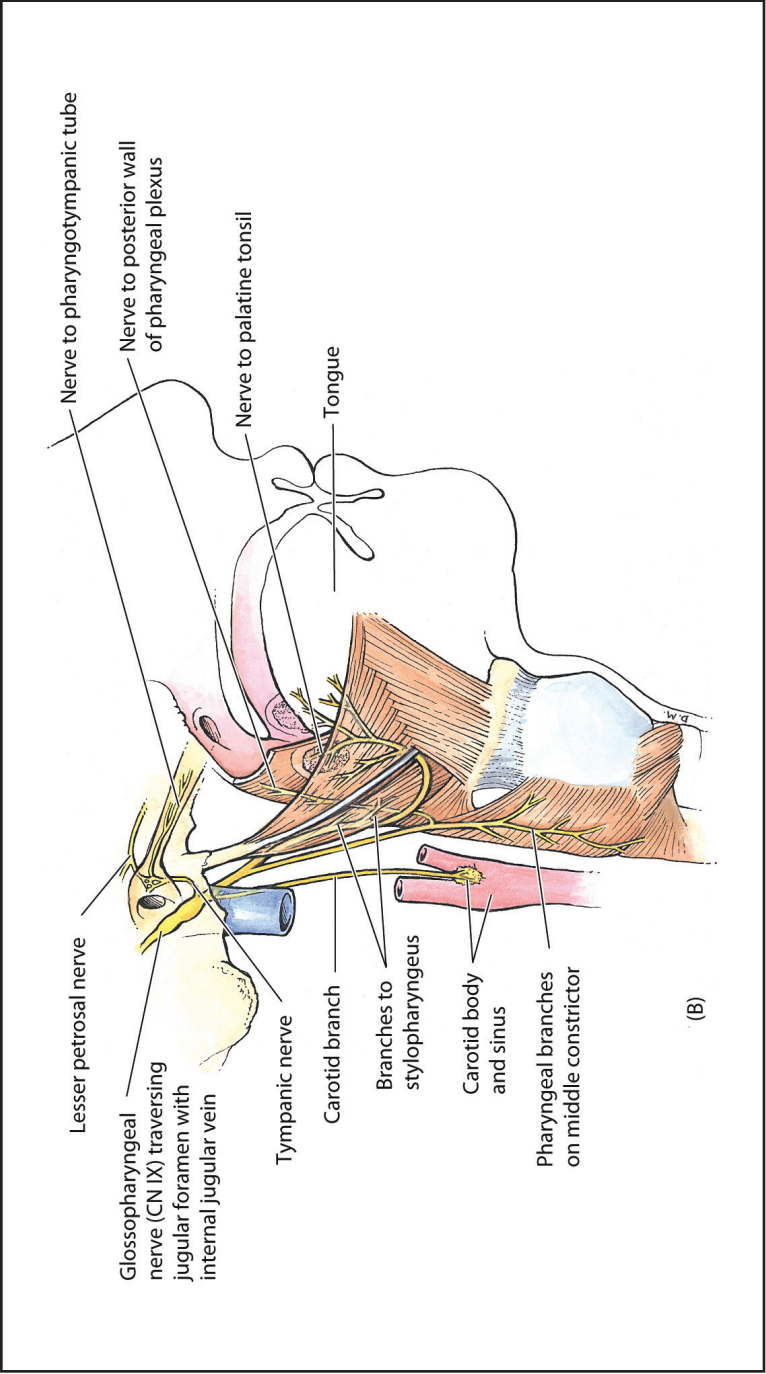
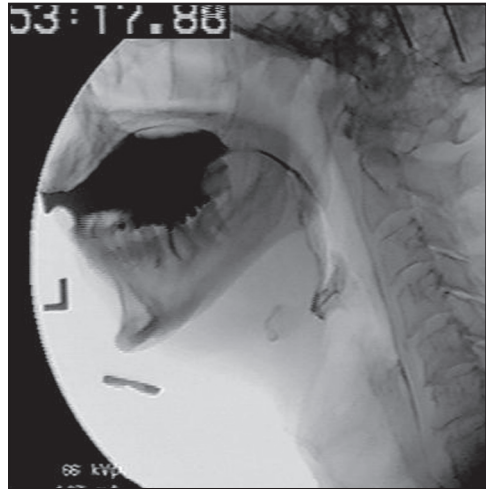


Figure 1-3. (continued)

Figure 1-4. Lateral view from videofluoroscopic swallowing study: oral phase. Note bolus in the oral cavity on the superior surface of the tongue. Palate closes against tongue base to close posterior oral cavity from oropharynx.



vagus nerve (X) via the pharyngeal plexus. The hyoglossus muscle (XII), and to a lesser extent the styloglossus muscle (XII), are active in posterior tongue depression. The anterior half of the tongue is then pressed against the maxillary alveolar ridge and the anterior half of the hard palate in rapid sequence, moving the bolus posteriorly on the dorsum of the tongue. Contraction of the orbicularis oris and buccinator muscles prevents pressure escape forward, out of the mouth, or laterally.

Soft palate elevation allows the bolus to pass through the tonsillar pillars. Once the soft palate is fully elevated, it contacts the adjacent pharyngeal walls in a valving action that acts to prevent penetration of the bolus or escape of air pressure into the nasopharynx. The side walls of the nasopharynx, consisting of the superior pharyngeal constrictor muscle, also oppose one another to make a more forceful closure of the nasopharynx (Figure 1-7). Motor nerve fibers from the vagus nerve (X) via the pharyngeal plexus innervate the superior pharyngeal constrictor and palatal musculature. The hyoid bone is then

moderately elevated in preparation for the pharyngeal phase of swallowing. Early hyoid bone elevation occurs primarily as a result of mylohyoid muscle contraction. Motor innervation of the mylohyoid muscle comes from a branch of the trigeminal nerve (V).

The muscles involved in the oral phase of swallowing represent three anatomical regions: the suprahyoid suspensory muscles (which affect the position of the posterior tongue and, thus, the hyoid bone), the muscles surrounding the tonsillar pillars, and the muscles involved in the closure of the nasopharynx. Muscles that discharge during the oral phase of swallowing include the muscles of the face (specifically those within the lips and cheeks), the tongue muscles, the superior pharyngeal constrictor, the styloglossus, stylohyoid, geniohyoid, and mylohyoid muscles with the palatoglossus and palatopharyngeus muscles demonstrating their maximal activity later. The anterior and posterior bellies of the digastric muscle participate in the subsequent elevation of the hyoid and larynx (see Figures 1-1A, 1-1B, and 1-6E).

Dysphagia Assessment and Treatment Planning Workbook

A TEAM APPROACH

Fourth Edition

Dysphagia Assessment and Treatment Planning Workbook

A TEAM APPROACH

Third Edition

Julie Barkmeier-Kraemer, PhD, CCC-SLP
Rebecca Leonard, PhD, CCC-SLP





5521 Ruffin Road
San Diego, CA 92123

e-mail: info@pluralpublishing.com
website: <http://www.pluralpublishing.com>

Copyright © 2019 by Plural Publishing, Inc.

Typeset in 11/13 Palatino by Flanagan's Publishing Services, Inc.
Printed in Korea by Four Colour Print

All rights, including that of translation, reserved. No part of this publication may be reproduced, stored in a retrieval system, or transmitted in any form or by any means, electronic, mechanical, recording, or otherwise, including photocopying, recording, taping, Web distribution, or information storage and retrieval systems without the prior written consent of the publisher.

For permission to use material from this text, contact us by
Telephone: (866) 758-7251
Fax: (888) 758-7255
e-mail: permissions@pluralpublishing.com

Every attempt has been made to contact the copyright holders for material originally printed in another source. If any have been inadvertently overlooked, the publishers will gladly make the necessary arrangements at the first opportunity.

ISBN-10: 1-63550-006-0
ISBN-13: 978-1-63550-006-6
Bundle ISBN: 1-63550-057-5

Contents

Introduction	vii
Acknowledgments	ix
Multimedia List	xi
1 Anatomy and Physiology of Deglutition Questions	1
2 Head and Neck Physical Exam Questions	17
3 Clinical Swallow Evaluation Questions	23
4 Endoscopy in Assessing and Treating Dysphagia Questions	49
5 Radiographic Evaluation of the Pharynx and Esophagus Questions	55
6 Dynamic Fluoroscopic Swallow Study: Swallow Evaluation with Videofluoroscopy Questions	61
7 DSS: A Systematic Approach to Analysis and Interpretation Questions	69
8 Dynamic Swallow Study: Objective Measures and Normative Data in Adults Questions	77
9 Other Technologies in Dysphagia Assessment Questions	89
10 The Treatment Plan Questions	93
11 Nursing Evaluation and Care of the Dysphagic Patient Questions	107
12 Nutritional Concerns and Assessment in Dysphagia Questions	113
13 Pediatric Clinical Feeding Assessment Questions	119
14 Esophageal Phase Dysphagia Questions	129
15 Neurogenic Dysphagia Questions	137
16 Dysphagia in Head and Neck Cancer Patients Questions	143
17 Laryngopharyngeal Reflux Questions	151
18 Spinal Abnormalities in Dysphagia Questions	157
Answers to Questions	163
References	229

Introduction

After teaching Dysphagia for 14 years at the University of Arizona, I find that the common denominator across every semester save my last one was a desire for a textbook and course format that integrated fundamental information about anatomy and physiology of the aerodigestive tract into clinically relevant knowledge needed to problem-solve the diverse range of individuals with feeding and swallowing problems. After using several textbooks that did not fully meet my needs, I found the Leonard and Kendall textbook and discovered that it contains nearly every element needed for training speech-language pathologists in dysphagia. I implemented the second edition of the Leonard and Kendall textbook in my graduate course on Dysphagia and found the magical combination of basic fundamentals as well as evidence-based models of interdisciplinary clinical practice. The contributions from every professional on the University of California–Davis (UCD) Voice, Speech, and Swallowing team added the necessary contribution of information from professionals in otolaryngology, nursing, dietary, speech-language pathology, and gastroenterology. The textbook also integrates a synopsis of the most recent and relevant literature about deglutition to propose evidence-based methods of assessment and treatment approaches. This continuity of update and revision to incorporate the latest evidence-based approach continues to be a unique contribution of the most recent edition of the Leonard

and Kendall textbook, *Dysphagia Assessment and Treatment Planning*.

This workbook was previously created to facilitate retention and improved application of content within the *Dysphagia Assessment and Treatment Planning* textbook. Based on feedback received by prior users of the workbook in academic classrooms, we have added course-friendly materials and online media for students and instructors on a PluralPlus companion website. Lecture materials are now provided when the textbook is adopted for a Dysphagia course. The workbook mirrors the *Dysphagia Assessment and Treatment Planning* textbook's reorganization of chapters. The format of the workbook also maintained the prior student-friendly approach for facilitating retention and application of information contained within the textbook. In addition, the workbook now provides a separate set of quiz/exam questions for each textbook chapter for use by course instructors. The prior workbook material providing instruction on qualitative and quantitative approaches to analyzing videofluoroscopic studies are now updated and available online.

We hope that the incorporation of online materials for the textbook and workbook provides improved instructional course materials and clinically relevant approaches for learning assessment and treatment approaches to dysphagia.

Acknowledgments

The authors gratefully acknowledge the contributions of colleagues at the UCD and at the University of Arizona who initially provided feedback on several of the original chapter materials developed for use in the workbook. Julie Barkmeier-Kraemer is also grateful to those providing feedback directly and indirectly regarding the use of the original workbook in an academic dysphagia course. Without this feedback, the ideas for the current range of course-based online materials would not have occurred. The co-authors of the textbook, Drs. Rebecca Leonard and Katherine Kendall, continue to be a source of inspiration by setting a standard for incorporat-

ing evidence-based practice and interdisciplinary expertise within their textbook. Their textbook offers one of the only such models of dysphagia practice that implements the recommended standard of care within a medical setting. I am honored to offer this supplementary set of learning materials to complement their superb model of dysphagia assessment and treatment. Finally, thank you to my husband and children for your unending understanding, patience, and support during the many hours spent developing the materials for this workbook as well as enforcing a well-balanced life.

Multimedia List

Chapter 4

Video 4–1. FEESPT1

Video 4–2. FEESPT2

Chapter 8

Video 8–1. BOLTRANSITSWALLGESTTIMING

Video 8–2. YngEldSwallow

Video 8–3. BCR

1

Anatomy and Physiology of Deglutition Questions

1. Define the following terms.

a. Deglutition

b. Feeding

c. Mastication

d. Swallowing

e. Bolus

f. Aspiration

g. Laryngeal penetration

h. Residue

i. Dysphagia

2. Match the following physiologic descriptions to their respective phase of deglutition.

- A. Preparatory
- B. Oral
- C. Pharyngeal
- D. Esophageal

_____ Propulsion of the bolus into the pharynx

_____ Mastication of the bolus

_____ Transportation of the bolus through the esophagus to the stomach

_____ The bolus is mixed with saliva

_____ Transportation of the bolus through the pharynx into the esophagus

_____ Airway closure occurs associated with cessation of respiration

_____ The soft palate begins to elevate as the posterior tongue depresses

_____ Bolus propulsion occurs through coordinated peristaltic contraction of both smooth and striated muscle

3. The skeletal framework that supports mastication includes all of the following bones

EXCEPT the

- a. mandible.
- b. maxilla.
- c. palatine.
- d. frontal.

4. The bony nasal septum is formed by these bones (fill in the blanks).

a. _____

b. _____

5. Match the phases of deglutition listed below with the correct image in Figure 1-1.

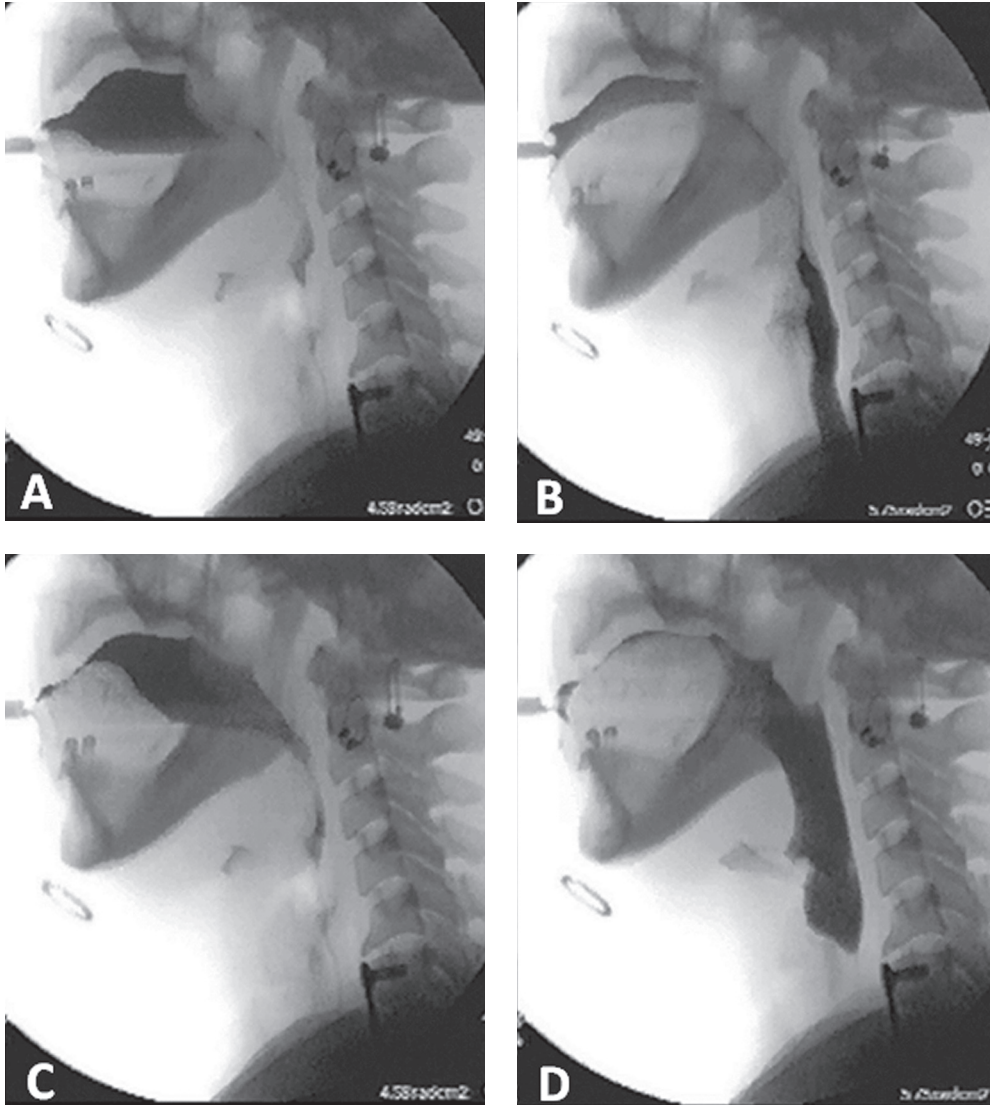


Figure 1-1

_____ Preparatory

_____ Pharyngeal

_____ Oral

_____ Esophageal

6. The floor of the nasal cavity is formed by these bones (select all that are correct).
- a. Ethmoid
 - b. Nasal
 - c. Palatine
 - d. Maxilla
7. The middle and superior conchae provide the lateral nasal skeletal framework for the middle and superior turbinates that extend into the nasal cavity from this bone.
- a. Sphenoid
 - b. Maxilla
 - c. Ethmoid
 - d. Palatine

8. Identify all of the skull bones comprising the cranium.

9. Identify the only mobile facial bone of the skull and the name of its joint.

10. Identify the cervical vertebrae typically associated with the location of the upper esophageal sphincter.

11. Identify all of the facial bones that form the skeletal framework for the oral cavity.

12. Identify the bone and particular portion of that bone through which the receptor organs for smell pass into the olfactory nerve.

13. Identify the muscles in Figure 1-2.

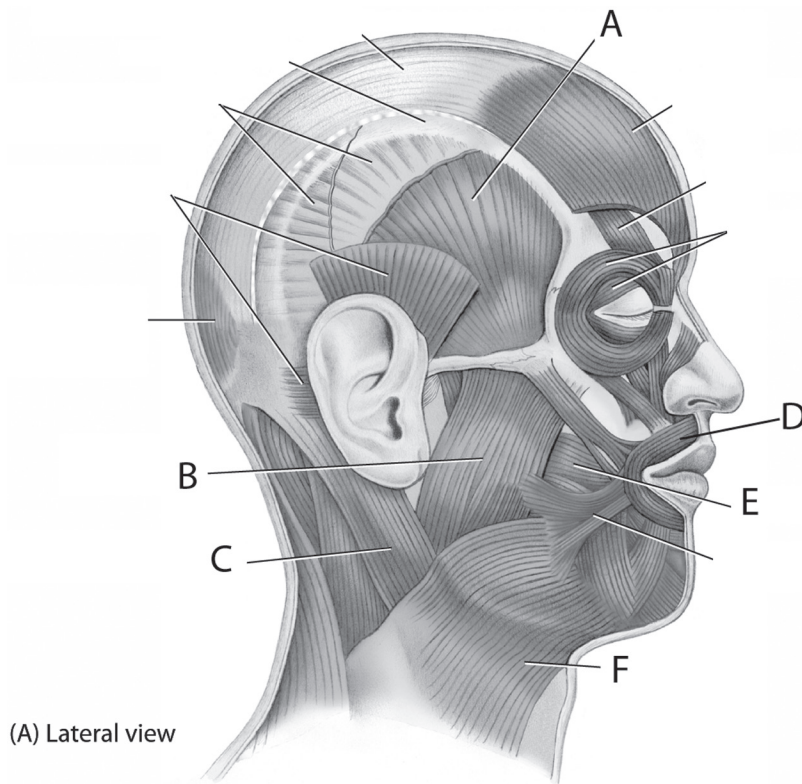


Figure 1-2

A _____

B _____

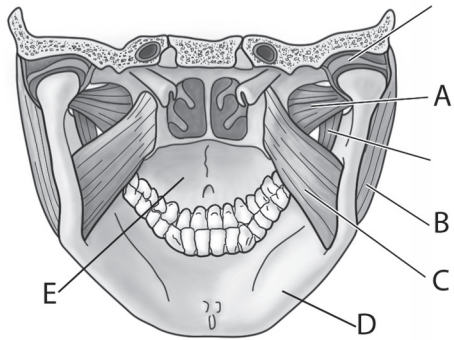
C _____

D _____

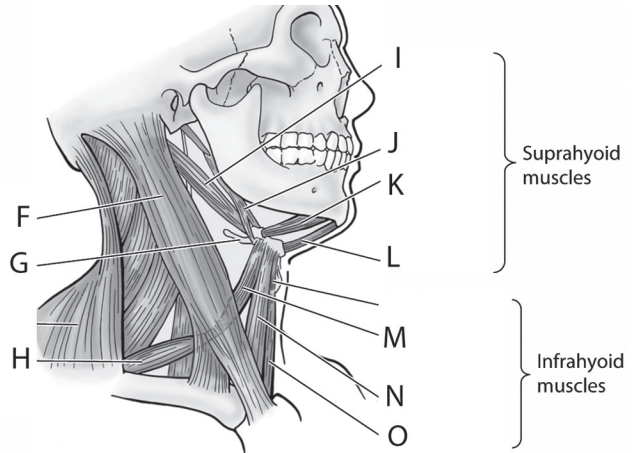
E _____

F _____

14. Identify the structures in Figure 1-3.



(D) Posterior view of viscerocranium



(E) Anterolateral view with head rotated slightly to left

Figure 1-3

- A _____
- B _____
- C _____
- D _____
- E _____
- F _____
- G _____
- H _____
- I _____
- J _____
- K _____
- L _____
- M _____
- N _____
- O _____