


Facial Paralysis

A Comprehensive Rehabilitative Approach



Mark K. Wax, MD



Contents

<i>Introduction</i>	<i>vii</i>
<i>Acknowledgments</i>	<i>viii</i>
<i>Contributors</i>	<i>ix</i>
1 Facial Nerve Anatomy and Mastoid Surgery in the Management of Facial Nerve Disorders <i>Frank M. Warren</i>	1
2 Facial Nerve Paresis and Paralysis: History, Etiology, and Testing <i>Steven B. Cannady and Oren Friedman</i>	11
3 Complications of Facial Paralysis <i>Mark K. Wax and Steven B. Cannady</i>	27
4 Medical Management of Facial Paralysis <i>Jessica J. Peck and Mark K. Wax</i>	41
5 Management of the Facial Nerve <i>Joshua D. Rosenberg and Eric M. Genden</i>	53
6 Nerve Substitutions in Facial Reconstruction <i>Cheryl C. Nocon and Alexander Langerman</i>	77
7 Management of the Paralyzed Brow <i>Fred Fedok, Parker Velargo, Frank Garritano, and Irina Chaikboutdinov</i>	101
8 Management of the Upper Eyelid Complex <i>Erika McCarty Walsh and Eben L. Rosenthal</i>	127
9 Management of the Lower Eyelid <i>Amy L. Pittman and John D. Ng</i>	145
10 Management of the Nasal Valve <i>Mark K. Wax and Jessica J. Peck</i>	165
11 Management of the Midface and Lips in the Paralyzed Face <i>Kristine A. Smith, Melynda Barnes, and Tom D. Wang</i>	181
12 Facial Reanimation with Free Tissue Transfer <i>Satyen Undavia and Babak Azizzadeh</i>	209
13 Management of the Soft Tissue Defect Following Parotidectomy <i>Christine G. Gourin and Mark K. Wax</i>	231
<i>Index</i>	<i>249</i>

Introduction

Facial paralysis can be a devastating process. A large spectrum of disease both systemic as well as localized can affect the function of the facial nerve. These effects can range from relatively minor and easily treated to complete paralysis with subsequent disability and life-threatening morbidity. More often than not the diagnosis, morbidity, and management of this disease are spread among different subspecialties of otolaryngology. Facial plastic surgeons, head and neck oncologic reconstructive surgeons, and general otolaryngologists will all have a role to play in the reconstruction and rehabilitation of patients with facial nerve paralysis.

Contemporary head and neck reconstruction involves the ability to approach the patients from a holistic perspective. Oftentimes textbooks or literature will deal with one particular aspect of morbidity from a particular subspecialty perspective. This textbook seeks to integrate the knowledge from the multiple subspecialties of otolaryngology that are all intimately involved in the rehabilitation and reconstruction of patients with facial nerve paralysis. The textbook will start with an introduction and a review of the anatomy of the facial nerve. Although most readers are intimately familiar with the anatomy of the facial nerve, the innervation, and physiology of facial function, a review

with the input of a neuro-otologist and how this integrates into the multidisciplinary approach to these patients will be rewarding.

The textbook will then look at the physiology and diagnosis of patients who present with facial nerve paralysis and the medical complications that are encountered. Medical management will then be covered as often it is needed to temporize the management until a definitive surgical approach can be undertaken. Then we will move on to management of the various structures affected by facial nerve paralysis. The textbook will cover topics ranging from the brow with the various options available for rehabilitation to reconstruction of the lower lip and lower facial defects. Also discussed is management of the parotid defect that although is not directly a result of the facial nerve paralysis is often seen in patients who have facial nerve paralysis secondary to the surgical ablation that required resection or removal of the nerve. Reconstruction will be discussed in anatomic segments.

It is my hope that this textbook will serve as a bridge among the different subspecialties that manage these patients and allow for translation of different surgical and technical processes to be integrated into the management of these patients.

5

Management of the Facial Nerve

Joshua D. Rosenberg and Eric M. Genden

Introduction

Facial paralysis results in a myriad of functional and cosmetic deficits including loss of spontaneous blink, oral incompetence, and facial asymmetry. If not corrected there is a risk of corneal injury, impairments in speech and swallowing, and social isolation. Affected patients identify themselves as not effective in expressing basic emotional states.¹ Significant social impairment and psychological distress have been identified in patients with facial nerve paralysis using a number of widely accepted quality-of-life instruments (Figure 5-1).²

The etiology of facial nerve injury is vast. While numerous techniques have been described to address all aspects of facial nerve injury, in the operative setting nerve grafting remains the best option for functional recovery. For the surgeon, the management of

the facial nerve and its reconstruction pose significant challenges in extra- and intratemporal oncologic surgery, skull base surgery, and head and neck trauma. This chapter is a review of the history of facial nerve grafting, special considerations in oncologic surgery, indications for nerve grafting, and a review of developing technologies.

History of Facial Nerve Grafting

The challenge of successful nerve grafting has been recognized throughout the history of medicine. Galen, whose work was performed during the second century AD, is credited with positing many of the basic concepts of the nervous system and its anatomy, including a basic understanding that nerve injury will result in permanent disability without treatment.³ Descriptions of nerve repair date back to at

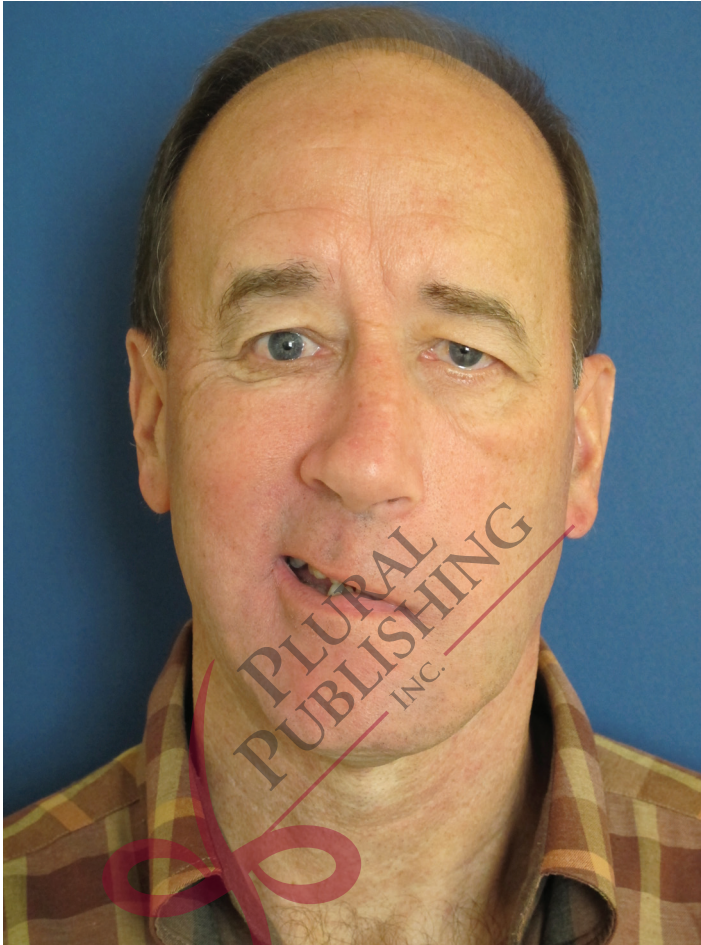


Figure 5–1. Patient with metastatic cutaneous squamous cell carcinoma presenting with facial nerve paralysis.

least the seventh century. Guglielmo Da Saliceto (1210–1280) described different types of nerve injuries and prescribed treatment based on the type of injury.⁴ Guy Du Chauliac, a French physician and surgeon, described firsthand experience with suture repair of severed nerves in his *Chirurgia Magna*, published in 1363.⁵ Additional sporadic reports of nerve repair using a variety of techniques, including suture anastomosis, were reported through-

out the Middle Ages, Renaissance, and Enlightenment. Starting in the late 1700s, modern understanding of nerve physiology began to develop. Advances throughout the late 19th century and 20th century demonstrated the utility of nerve repair. This not only included the validity of direct suture anastomosis but also nerve grafting in cases where the severed nerve could not be co-apted. In 1889 Robson reported the first successful human nerve graft, using a

posterior tibial nerve harvested from one patient's amputated limb to bridge a 6-cm gap in the median nerve of a 14-year-old girl. The defect was created during tumor extirpation. At 3 years follow-up, he deemed the functional results as "perfect."⁶

Reflecting the historical developments of peripheral nerve repair, modern understanding and treatment of the facial nerve began in the 18th century. In that period, Sir Charles Bell is widely recognized for his description of the facial nerve as the mediator of facial expression and the natural history of facial nerve injuries. For his efforts a number of anatomic, physiologic, and pathologic phenomena bear his name, including Bell's palsy, the term used to describe idiopathic facial nerve paralysis.

Driven by the advent of cortical mastoidectomy for suppurative mastoiditis and its common sequelae of facial nerve palsy, interest in facial nerve repair increased in the second half of the 19th century. In 1879 Drobnick reported the first nerve substitution connecting the facial nerve to the spinal accessory nerve (CN VII–XI).⁷ Facial nerve substitution procedures became the standard of care into the early 20th century. Popular donor nerves included CN IX, XI, and XII. The first successful facial nerve repair was reported in 1925 and in 1933 Duel noted superior results with direct repair versus facial nerve substitution procedures.⁴

Development in understanding and treating all aspects of facial nerve palsy continued throughout the 20th century. Improved neurosurgical and otological techniques allowed access to the entire length of the facial nerve. Additionally, the incidence of surgical injuries to the

facial nerve in these settings decreased dramatically with the widespread use of binocular microscopy.⁷

However intracranial/temporal and extratemporal surgery, especially parotid gland surgery, and trauma remained important causes of facial nerve injury. A variety of techniques were described to address all aspects of facial nerve paralysis. Jobe described lid loading with a gold weight to improve eyelid closure in 1974. In 1976 Harii described use of a free gracilis transfer for smile reanimation. Since that time these techniques along with other periocular procedures and muscle and fascial slings have been modified and refined. Today, patients presenting with facial nerve pathology and their treating physicians have a wide variety of options easily adaptable to each patient's specific needs. Nonetheless, primary suture anastomosis, nerve cable grafting, and/or nerve substitution procedures remain the first-line options for all facial nerve injuries be they iatrogenic or traumatic.

Oncologic Considerations and the Facial Nerve

Relevant facial nerve anatomy includes its emergence from the brainstem at the cerebellopontine angle to its distal branches innervating the musculature of facial expression. An in-depth discussion of the facial nerve's anatomy is beyond the scope of this chapter, but relevant aspects of its course are important when considering the management of neoplasms that may arise at all points along the course of the facial nerve.

The facial nerve exits the brainstem at the pons accompanied by the *nervus intermedius*. This intracranial segment extends for approximately 24 to 28 mm until it reaches the internal auditory canal. It then traverses the internal auditory canal (IAC) as the meatal segment. The nerve abruptly turns at the fundus of the IAC beginning the labyrinthine segment, which follows a short course to the geniculate ganglion. It then enters the middle ear as the tympanic segment. As it enters the mastoid it again turns (the second genu) and travels to the stylomastoid foramen. The extratemporal portion of the nerve begins at the stylomastoid foramen. As the nerve traverses the parenchyma of the parotid gland, it divides into lower and upper portions at the *pes anserinus*. The nerve further divides into five main branches: the frontal/temporal, zygomatic/infrorbital, buccal, marginal, and cervical branches. Significant arborization may exist between branches along with variation in the origin of the buccal branch between the upper and lower divisions. As the terminal branches exit the parotid gland they traverse the anterior surface of the masseter muscle deep to the superficial musculoaponeurotic system (SMAS).

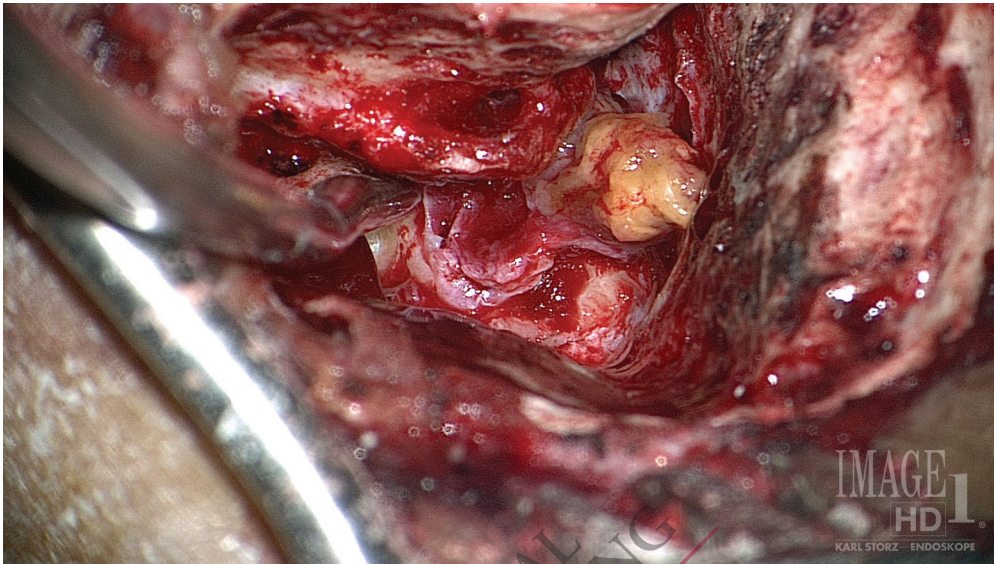
Intratemporal Tumors Affecting the Facial Nerve

Intratemporal neoplasms commonly cause facial nerve deficits. Nerve sheath tumors or vestibular schwannomas (often referred to as acoustic neuromas), arise from Schwann cells and are the most frequent type of neuroma of the head and neck. Neuromas of the facial nerve are much less common

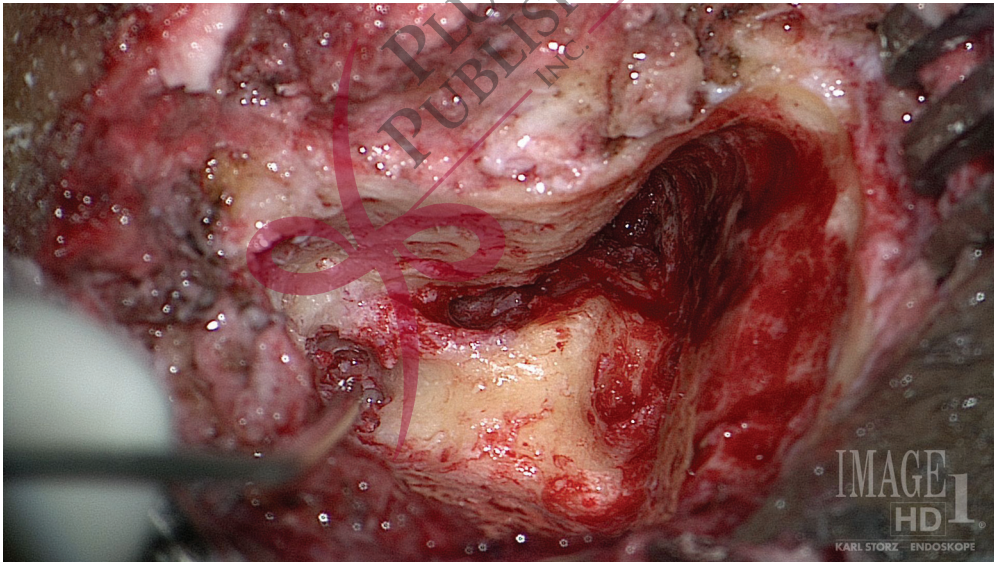
with a reported incidence of approximately 1% (Figure 5–2).⁸ They are typically benign although rare instances of malignant facial nerve schwannomas have been reported.⁹ Both vestibular schwannomas and intrinsic facial nerve neuromas typically affect facial nerve function via compression or injury at the time of treatment. Less common intratemporal tumors that may involve or affect the facial nerve include hemangiomas and meningiomas. Like other benign intratemporal neoplasm, facial nerve palsy is usually the result of direct compression.

Intratemporal malignancies are much less common. Skull base malignancies of varying origin, including salivary gland, squamous cell carcinoma, and sarcomas may affect the intratemporal facial nerve. The facial nerve also provides a route for the spread of neoplastic disease into the temporal bone via perineural invasion. Mucoepidermoid carcinoma, adenoid cystic carcinoma, and squamous cell carcinoma of the skin are well documented to spread perineurally via the facial nerve into temporal bone (Figure 5–3).

For benign tumors that do not intrinsically arise from the facial nerve or facial nerve tumors that do not require resection, preservation of the facial nerve is a key tenet of surgical management. Using modern microsurgical technique and nerve monitoring, preservation with minimal nerve trauma and limited or no resultant facial nerve palsy is the norm. In instances where nerve preservation is not possible, nerve repair via primary anastomosis or grafting is indicated.¹⁰ When nerve repair is not possible either through end-to-end coaptation or grafting, nerve substitution procedures and facial nerve reanimation procedures should be undertaken.



A



B

Figure 5-2. Facial nerve schwannoma in mastoid cavity. **A.** Prior to resection. **B.** After resection.

Extratemporal Tumors of the Facial Nerve

As the facial nerve exits the stylomastoid foramen it enters the parotid gland.

The gland, rich in epithelial and stromal elements, is the site of origin of a variety of benign and malignant neoplasms. It is also a known nodal drainage basin for the scalp and upper face and